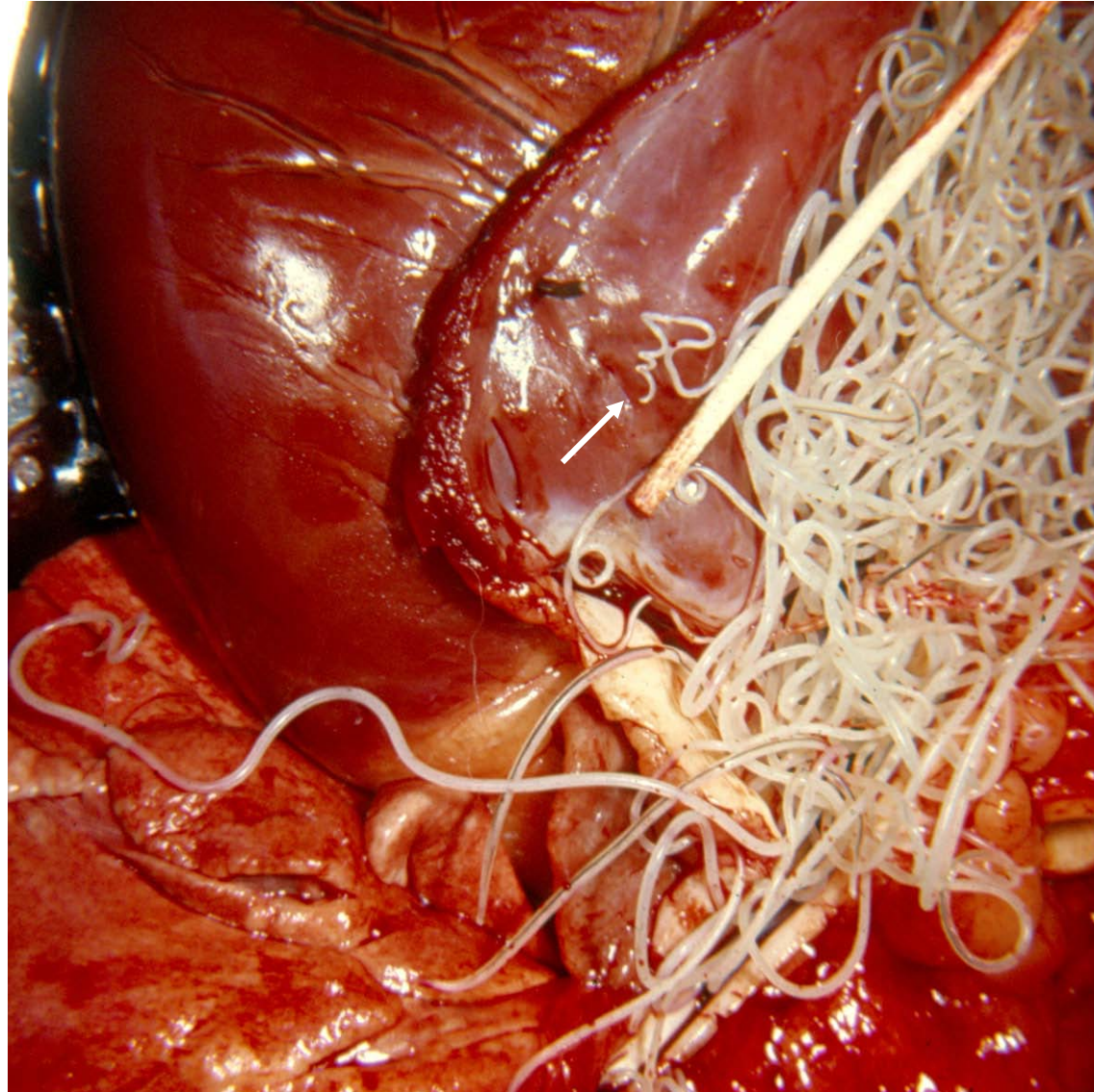


Note: Materials in this presentation are from the veterinary parasitology collection, Texas A&M University, College of Veterinary Medicine (1970).

Dirofilaria immitis, dog heartworm. Right ventricle of heart (cut open).
Male with “corkscrew tail” indicated by arrow, others are females.



Microfilariae in blood of dog: a, *Dirofilaria immitis* (note straight tail and relatively robust body); b, *Dipetalonema reconditum* (with curved tail and slighter body).

e, erythrocyte;
m, monocyte;
p, "poly" or PMN.

